Case of a 17-Year-Old with Incidental Tuberculous Liver Abscess: A Case Report

Dixie Joice C. Lomaad, MD[1], Jeremy Jones F. Robles, MD, FPCP, FPCEDM[1,2]

Background. Tuberculosis (TB) has long been a recognized infectious disease contributory to worldwide mortalities. Most cases are from low- to middle-income countries, including the Philippines. Hepatobiliary TB comprises only a small portion of extrapulmonary TB. Tuberculous liver abscess (TLA) usually presents with nonspecific findings causing delay in the diagnosis. Due to this, further reports are needed for early detection along with timely treatment for future courses.

Case. Presenting a 17-year-old male who came in with right upper quadrant abdominal pain associated with intermittent fever. The symptoms persisted and eventually progressed to abdominal distention, weight loss and jaundice. Initial laboratories were taken including an ultrasound finding of a complex lesion in the hepatic lobe. He was initially managed with empiric antibiotic therapy – Ciprofloxacin and Metronidazole, however, despite it, there was persistence of right upper quadrant pain, abdominal distention and jaundice. Due to this, further work-up was done with drainage of the abscess. Cultures were taken revealing tubercle bacilli along with other microbial growth. Antibiotics and antituberculosis medications sensitive to the microorganisms were started. With the noted improvement of jaundice and abdominal distention and resolution of pain and fever, he was discharged.

Conclusion. Tuberculous liver abscess is an uncommon presentation of extrapulmonary tuberculosis in an immunocompetent male with right upper quadrant abdominal pain and jaundice. Although TB is endemic in the Philippines, this gastrointestinal involvement is often not immediately recognized. Thus, with any suspicion of liver abscess, tuberculous (TLA) type should be included in the differentials for early diagnosis and management.

Keywords. tuberculosis, extrapulmonary, liver abscess, TLA

Introduction

Tuberculosis (TB) has long been a recognized disease affecting humans contributing to infectious mortalities worldwide. Approximately 80% of cases occur from low- to middle-income countries with the largest percentage from the Southeast Asian Region, including the Philippines. Hepatobiliary TB comprises 3.5% of the extrapulmonary TB worldwide [1, 2]. On recent studies, it is observed to be rising in Asian countries, predominantly among Filipinos due to its endemicity. Although there is no further explanation to support this, it is believed that there is also racial vulnerability to tubercle bacilli [3]. In the Philippine national TB report last 2020, the incidence of tuberculosis nationwide is about 85%. This consists of both bacteriologically and clinically diagnosed cases. Extrapulmonary tuberculosis was noted to occur 2-3% nationwide annually. This is commonly occurring in males with a male to female ratio of 2:1 and of no specific age but in one study, the age range was noted to be between 11-50 years. Among the sites involved in TB, gastrointestinal tract is only the sixth of the different extrapulmonary types with the most common being the ileocecal region. However, hepatobiliary involvement presents with nonspecific symptoms causing delay in the diagnosis [3].

Tuberculous liver abscesses usually occur in children and different ethnic groups. Although there are studies supporting presentations for those diagnosed with hepatobiliary TB, including tuberculous liver abscesses (TLA). Due to the rarity of TLA cases, further reports are still deemed necessary for early detection along with timely treatment for future courses [1, 4].

Case Presentation

This is a case of a 17-year old Filipino male student with no known comorbidities – asthma nor other medical conditions – who was admitted for right upper quadrant abdominal pain associated with intermittent fever. He has no maintenance medications, nor known food and drug allergies. Upon extraction of history, there were no previous hospitalizations nor prior treatment with

[1]Department of Internal Medicine, Cebu Institute of Medicine – Cebu Velez General Hospital, F. Ramos Street, Cebu City, Philippines
[2]Section of Endocrinology, Diabetes, and Metabolism, Department of Internal Medicine, Chong Hua Hospital, Cebu City, Philippines
Corresponding author: Meghan Marie Aliño, M.D.
Email: meghanalino@gmail.com

tuberculosis. He is a non-smoker, non-alcoholic drinker, and claims to have no illicit drug use. He also claims to have no sexual history. Symptoms of right upper quadrant pain along with intermittent fever started about 2 months prior to his admission. Associated symptoms of cough, coryza, night sweats, chills, weight loss, anorexia, nausea, vomiting, altered mental status, jaundice, abdominal distention, chest pain, and dyspnea were not noted. No consult nor intervention was done at the time due to financial constraints. Along the weeks prior to his admission, the right upper quadrant pain and fever persisted now with associated weight loss and jaundice. Thus, his family decided for hospitalization and was initially admitted at a local secondary hospital where he underwent laboratories including abdominal ultrasound revealing a large, complex lesion in the right hepatic lobe with non-specific gallbladder wall thickening. With this impression, he opted to seek further management and was referred to a tertiary hospital.

Figure 1. Whole Abdominal Ultrasound: Liver is in normal in size with normal parenchymal echogenicity. Multiple inhomogenous masses (pointed by yellow arrows) with largest at the left hepatic lobe measuring 5.24 cm x 4.39 cm x 6.62 cm.

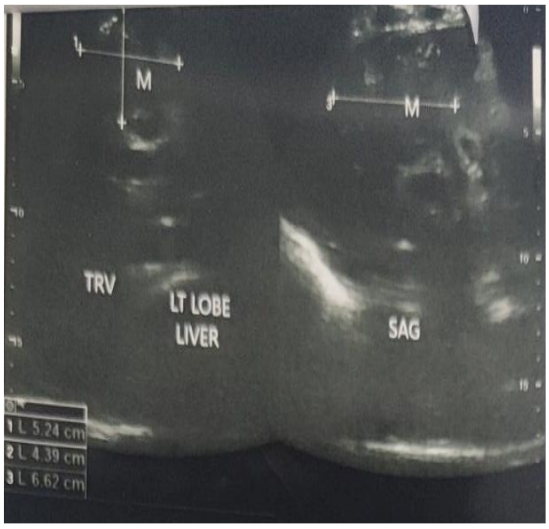

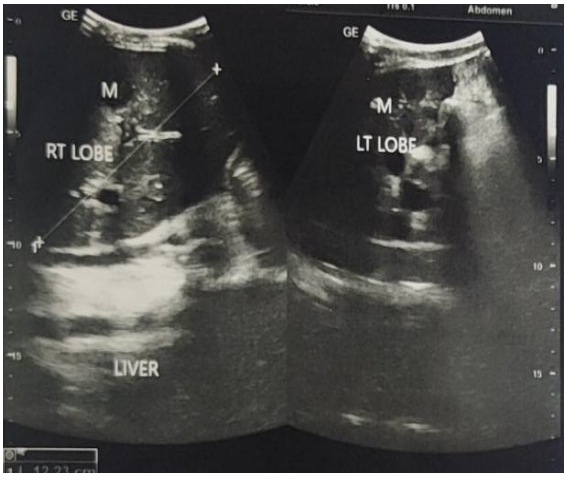

At our institution, upon examination, vital signs were within normal limits. His pertinent physical findings were jaundiced skin, icteric sclerae, and a distended abdomen with tenderness on light and deep palpation over the right hemiabdomen. His body mass index was 18 kg/m^2 (underweight). Chest and lung findings were with equal chest expansion; clear breath sounds and no adventitious sounds. There were also no palpable lymphadenopathies appreciated. Laboratory examinations at the time of presentation are summarized in Table 1.

He was initially treated as a case of pyogenic liver abscess with empirical antibiotic therapy of Ciprofloxacin 500mg orally twice a day and Metronidazole 500mg orally three times a day. However, after 2 days of the antibiotics, there was noted persistence of right upper quadrant pain, abdominal distention and jaundice deeming for further work-up – including imaging.

Figure 2. Chest X-ray: Suspicious bilateral apical nodules (shown by yellow arrows). To consider tuberculosis

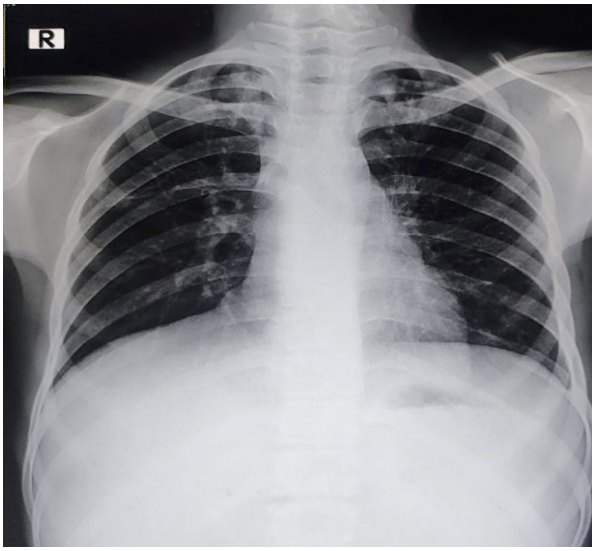

Figure 3. CT scan with contrast: (pointed by yellow arrows) Multiple rim enhancing hepatic nodules and masses with areas of necrosis and calcification associated with intrahepatic biliary ectasia and wall thickening of the common hepatic duct in the porta hepatis





CT scan with contrast was done with findings noted to have hepatic nodules and masses with areas of necrosis and calcification. This then prompted the service for an ultrasound-guided core needle biopsy. During the procedure, an amount of 80cc of milky green viscous fluid from the hepatic abscess was drained and the specimen was sent for gram stain, culture and sensitivity, Gene Xpert and histopathologic studies.

Eventually, results of the different tests showed an organism of Klebsiella aerogenes that was sensitive to the started oral Ciprofloxacin. However, due to the progression of fever and abdominal pain, the antibiotics were shifted intravenously. Gene Xpert of the abscess revealed MTB detection without rifampicin resistance and the histopathology report showed extensive necrosis with inflammation consistent with abscess. He was then started on oral anti-tuberculosis treatment (Rifampicin(R)+Isoniazid(H)+Pyrazinamide(Z)+Ethambutol(E) 150/75/400/275 mg/tab) – four-drug fixed combination. With the patient's weight of 47kg, a four-drug combination and a dose of 3 tablets daily for 2 months for the intensive phase, and shifting to two-drug (HR) fixed combination with a dose of 3 tablets daily for the next 4 months. Over the course of his admission, he was observed to have resolution of his fever and abdominal pain with subsiding jaundice, now with sallow skin and slightly icteric sclerae, and abdominal distention. However, despite this, there were already noted missed doses of the antibiotics due to financial constraints. With these observations on the examination, the service opted the antibiotic intravenous routes be shifted to oral routes. Subsequently, there was gradual improvement of the patient's overall condition. He was then advised for follow-up with his attending physician but was lost to follow-up thereafter.

Figure 4. Histopathology Report: Extensive Necrosis with Acute/Chronic Inflammation consistent with abscess

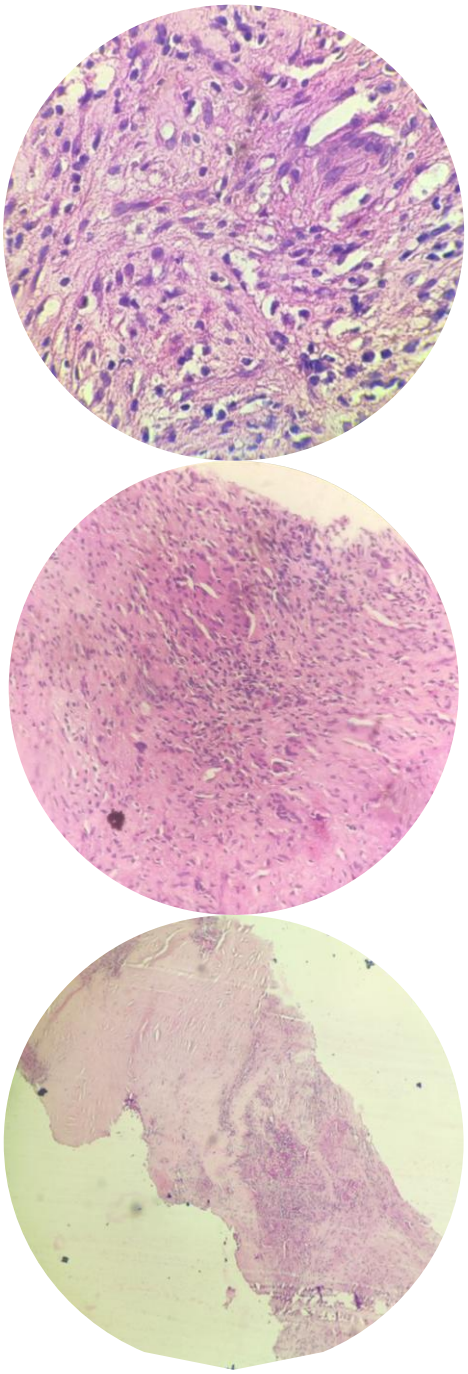

Discussion

Hepatic tuberculosis is considered a rare form of extrapulmonary tuberculosis and often occurs along with pulmonary or enterocolitis conditions. Due to the low oxygen concentration in the liver, it becomes a hostile environment for tubercle bacilli to grow. Various studies

described three types of hepatic TB: (1) pulmonary or miliary tuberculosis with diffuse hepatic involvement, (2) primary miliary tuberculosis of the liver without pulmonary involvement, and (3) tuberculous liver abscess. Through hematogenous dissemination, tubercle bacilli access the liver via the hepatic artery or the portal vein [4, 5, 6, 7]. In a local journal by Cua et al, incidence of hepatobiliary tuberculosis in the Philippines is still considered rare. However, the age range on their data gathered were more of adolescent age (11-15 years old). Most of the patients came from a low socioeconomic status and were noted to be malnourished. [8] Our patient was noted to be under low economic status due to their approach of his condition that they waited for 2 months before seeking medical help. Upon examination, the patient was also noted to be malnourished with an index of 18 kg/m^2 considered to be underweight. This likely contributed to the patient's state to have contracted the infection as TB is endemic in the Philippines.

Most common presentations for hepatobiliary TB are fever, weight loss, and abdominal pain, especially on the right upper quadrant. Hepatomegaly and splenomegaly are also one of the frequent physical findings. Jaundice may also be present; however, this usually occurs if there is biliary involvement. This can be due to obstruction, pericholangitis, or direct involvement of the biliary ducts [3, 4, 7]. Most series show right upper quadrant pain being the most common symptom [1]. Our patient presented initially with right upper quadrant pain with intermitted fever. However, because of the lack of concern, the condition was tolerated and now progressed to abdominal distention and jaundice. As the patient's liver has already been affected, surrounding structures have been compromised. In this case, the peritoneum and the biliary ducts supported by the presentation of abdominal distention and jaundice. Mostly, tuberculous liver abscess is present in immunocompromised individuals. Its presentation is also nonspecific – weight loss, fever, and pain [3, 4, 7, 9]. With the patient presenting with constitutional symptoms, the factor of being malnourished led to the patient's immunocompromised state leading to his deterioration of a preventable disease when treated early on.

Blood work up to identify hepatobiliary TB nor tuberculous liver abscess would show nonspecific results. Liver function tests – aspartate aminotransferase, alanine aminotransferase, alkaline phosphatase, gamma-glutamyl transpeptidase, total protein and albumin-globulin ratio are elevated, but nonspecific. Thus, these are not the confirmatory diagnostic tests [1, 3, 4, 7]. As shown in the appendix, this patient had elevated liver enzymes but this is likely due to the infection occurring in the liver.

About 75% of patients with hepatic TB present with abnormal chest x-rays which is consistent with this case noting suspicious apical nodules. In tuberculous liver abscess and pseudotumoral liver TB, ultrasound results show complex masses and hypoechoic lesions, be it solitary or multiple. However, this cannot be distinguished from carcinoma [1, 10]. Thus, higher definition imaging – computed tomography (CT) and magnetic resonance imaging (MRI) – aids to diagnose tuberculoma or tuberculous liver abscess. CT scan findings of liver tuberculoma are described to be non-enhancing, central, low-density lesion from the caseation necrosis with a slightly enhancing peripheral rim representing the granulation tissue [4, 7, 10, 11]. With the patient's CT scan findings, it showed rim enhancing nodules consistent with what can be found in CT scan results of tuberculous liver abscess. To confirm the diagnosis, aspiration and biopsy should be done. Histopathology reports show evidence of granulomas (epithelioid type) or culture of the biopsy specimen detects acid fast bacilli (AFB) or positive in TB geneXpert. AFB stains are positive and mostly common in tuberculous liver abscess as they are abundant in liquified caseous material [3, 4, 5, 7]. With our patient, histopathology revealed inflammation that was consistent with an abscess. No granulomas were noted. However, TB GeneXpert was taken with detection of MTB which confirms the diagnosis of our patient.

Once the diagnosis is confirmed, antituberculosis therapy must be initiated immediately. As per the National TB Guidelines in the Philippines, Rifampicin(R)+Isoniazid(H)+Pyrazinamide(Z)+Ethambutol(E) 150/75/400/275 mg/tab is a fixed four-drug combination that is given during the intensive phase and shifted to two-drug combination for maintenance phase. Doses are weight-based: (1) 25-37 kg, 2 tablets; (2) 38-54 kg, 3 tablets; (3) 55-70 kg, 4 tablets; and (4) >70 kg, 5 tablets. [12] Some studies would recommend 6-, 9-, or 12-month duration. However, the 6-month duration already shows successful results. As per the local guidelines, quadruple therapy for the first two months then tapered to two drug therapy for the next 4 months to complete 6 months had promising results with lesser chances of lost to follow-up and poor compliance to medications. Some would undergo percutaneous drainage followed by antituberculosis therapy via catheter infusion directly to the hepatic lesion. Studies showed good prognosis for these types of treatment [5, 10, 12, 13]. The case is a typical presentation for patients with tuberculous liver abscess. He was also responsive to the started treatment of 2HRZE/4HR. However, due to the rarity of cases here in the Philippines, there is still need for further surveillance and workup for these types of conditions.

Conclusion

Although endemic in the Philippines, this case is still an uncommon presentation of extrapulmonary tuberculosis as tuberculous liver abscess (TLA). It usually occurs in patients with associated infections, including those of immunocompromised states.

Symptoms, physical examination, blood tests, and radiologic findings of this disease are non-specific. The primary test to confirm diagnosis is demonstration of acid-fast bacilli (AFB) of aspirated drainage, pus culture

of Mycobacterium tuberculosis, positive GeneXpert MTB/Rif, ELISA and PCR for M. tuberculosis.

Thus, in any patient with suspicion of liver abscess, especially in endemic TB regions, tuberculous liver abscess should be part of the differentials as its presentation portrays similar intraabdominal infections (e.g. pyogenic and amebic liver abscess). If diagnosed early on, treatment of 2HRZE/4HR will suffice and prevent disease progression.

Informed Consent

Informed consent was obtained after a thorough explanation of the patient's condition, the incidence especially in the adolescent population regarding the said condition, and the contribution it could make in the management of GI TB by making a case report.

Disclaimer and Disclosure

The author declares no conflict of interest regarding the publication of this paper. The data presented in this article are expressed from the author and not of the institution.

References

1. P. Chaudhary, "Hepatobiliary Tuberculosis," Annals of Gastroenterology, 2014.
2. W. H. Organization, WHO, 2023.
3. E. Abdelmahmuod, M. Elayana, E. Subahi, L. Aker, M. Alamin and G. Alfitori, "Tuberculous liver abscess as a unique cause of liver abscess: A case report and literature review," CellPress, 2023.
4. V. H. Chong, "Hepatobiliary Tuberculosis: A Review of Presentations and Outcomes," The Southern Medical Association, 2008.
5. M. Akcay, Polat K.Y., D. Oren and G. Ozturk, "Primary Tuberculous Liver Abscess: A case report and review of literature," Blackwell Publishing, 2004.
6. D. o. Health, National Tuberculosis Program, Manual of Procedures, Philippines, 2020.
7. C.-c. Huang, T.-C. Chen, L.-T. Chou, A.-B. Lai and J.-H. Wang, "Isolated tuberculous liver abscess in an immunocompromised adult patient: A case report and literature review," Elsevier, 2013.
8. M. Hemmatian, K. Toolabi, S. Shokouhi and S. Tehrani, "Tuberculous Liver Abscess in an Immunocompetent Patient: A Case Report," National Research Institute of Tuberculosis and Lung Disease, 2014.
9. A. D. Karaosmanoglu, M. R. Onur, D. Sahani, A. Tabari and M. Karcaaltincaba, "Hepatobiliary Tuberculosis: Imaging Findings," inRadiology, 2016.
10. Y. E. Mahdaouy, Y. E. Brahmi, N. Njoumi, H. Chahdi, M. Moujahid, A. Ehirchiou and A. Zentar, "Primary Tuberculous Abscess of the Liver: A Case Report and LIterature Review," Elixir, 2018.
11. D. Reed, A. Nash and P. Valabhji, "Radiological diagnosis and management of a solitary tuberculous hepatic abscess," The British Journal of Radiology, 1990.
12. [J. Loscalzo, D. Kasper, D. Longo, A. Fauci, S. Hauser and J. L. Jameson, Harrison's Principles of Internal Medicine, McGraw Hill LLC, 2022.
13. D. o. H. -. Philippines, "National Tuberculosis Program Manual of Procedures," no. 6th Edition, 2020.
14. L. Cua, M. L. Villabroza, A. Avendano, J. Santos and S. Sadang, "Clinical profile and outcome of patients with abdominal tuberculosis, a 20-year PCMC experience," 2004.

Appendix

Table 1. TABLE OF INPATIENT LABORATORY EXAMINATIONS

HEMATOLOGY

Parameter	Hospital Day 1	Hospital Day 3	Hospital Day 7	Hospital Day 13	Reference Range
WBC count, 10^3/uL	20.8		41.6	15.3	4.10-10.9
Neutrophils, %	77.4		88.5	74.4	47-80
Lymphocytes, %	11.8		6.29	15	13-40
Monocytes, %	8.32		4.65	7.31	2-11
Eosinophils, %	1.64		0.191	2.35	0-5
Basophils, %	0.874		0.351	0.953	0-2
Hemoglobin, g/dL	9.04		9.18	8.09	13.5-17.5
Hematocrit, %	26.8		28.3	25.4	41-53
Platelet Count, 10^3/uL	291		370	371	140-440
Prothrombin Time, seconds	16.1	17.4			11.6
% activity	52.8	46.9			100
INR	1.36	1.48			
HIV	NEGATIVE				

CLINICAL CHEMISTRY

Parameter	Hospital Day 1	Hospital Day 5	Hospital Day 13	Hospital Day 20	Reference Range
Serum Creatinine, mg/dL	0.6	0.6		0.4	0.72-1.25
Alanine Aminotransferase (SGPT), U/L	33.85		<6		0-55
Total Bilirubin, mg/dL	1.96				0.2-1.2
Direct Bilirubin, mg/dL	1.3				0-0.5
Indirect Bilirubin, mg/dL	0.66				0.2-0.7

DRAINAGE RESULTS

Parameter	Findings
Hepatic Abscess Drain Culture & Sensitivity	Klebsiella aerogenes • Sensitive: Piperacillin-Tazobactam, Cefotaxime, Ceftazidime, Ceftriaxone, Cefepime, Ertapenem, Imipenem, Meropenem, Amikacin, Gentamicin, Ciprofloxacin, TMP-SMX • Intermediate: Colistin • Resistant: Amoxicillin-Clavulanic avid, Cefuroxime, Cefoxitin
Hepatic Abscess TB Gene Xpert	MTB is DETECTED
Core Needle Biopsy	Extensive necrosis with Acute/Chronic Inflammation consistent with abscess

IMAGING

Parameter	Findings
Chest X-ray	• Suspicious bilateral apical nodules. To consider tuberculosis
CT scan of Whole Abdomen with Contrast	• Multiple rim enhancing hepatic nodules and masses with areas of necrosis and calcification associated with intrahepatic biliary ectasia and wall thickening of the common hepatic duct in the porta hepatis. Consider hepatobiliary TB, Neoplastic process is not ruled out • Retroperitoneal and mesenteric rim enhancing necrotic lymphadenopathies

Figure 1. TIMELINE OF PATIENT'S COURSE FROM ONSET OF SYMPTOMS

